The Unofficial Guide to Radiology: 100 Practice Abdominal X-Rays with Full Colour Annotations and Full X-Ray Reports

FIRST EDITION

Authored by

DANIEL WEINBERG MBCHB (Hons) MPHIL
Radiology Registrar
Central Manchester NHS Foundation Trust

REBECCA BEST BSc (Hons) MBBCh
Academic Foundation Doctor
Queen Elizabeth University Hospital, Glasgow, UK

LYDIA SHACKSHAFT
Medical Student
Kings College London, UK

Edited by

MARK RODRIGUES BSc (Hons) MBCHB (Hons) FRCR
Radiology Registrar,
Edinburgh Royal Infirmary, Edinburgh, UK

ZESHAN QURESHI BM BSc (Hons) MSc BM MRCPCH FAcadMEd MRCPS (Glasg)
Paediatric Registrar,
King's College Hospital, London UK.

ZESHAN QURESHI

ISBN 978-1910399033

Edited by Mark Rodrigues and Zeshan Qureshi
Authored by Daniel Weinberg, Rebecca Best, Lydia Shackshaft

Published by Zeshan Qureshi. First published 2020.

Original design by Zeshan Qureshi and SWATT Design Ltd. Page make-up by Amnet.

Cover Design by Anne Bonson-Johnson.

A catalogue record for this book is available from the British Library.

Editor's Acknowledgements:

We would like to thank all the authors for their hard work, and our panel of student reviewers for their unique input. We are extremely grateful for the support given by medical schools across the UK, Europe and Australia. We would also like to thank the medical students that have inspired this project, believed in this project, and have helped contribute to, promote, and distribute the book across the UK.

Printed and bound by Jellyfish Print Solutions Ltd.

DEDICATION

Daniel would like to dedicate this book to his lovely partner Sarah, for her tremendous support over the years he has known her. Daniel would also like to thank his parents Ray and Karen for spurring him on to apply for a career in medicine and their endless support and guidance throughout his career to date. He would not have ever been in a position to write this book without them.

Rebecca would like to dedicate this book to her sisters Lana and Louise, who inspire her every day with their enthusiasm, kindness and resilience.

Lydia would like to dedicate this book to her beautiful Mum, for every single thing her mum did to get Lydia where she is today; for always putting Lydia's education before her own desires, for her never-ending encouragement and her belief that Lydia could achieve anything, and for sharing with Lydia her absolute wonder at the world.

INTRODUCTION

Whilst it could be argued that the abdominal X-ray is becoming an outdated radiological investigation in modern day medicine with the advent and ever-increasing use of CT and MRI, it remains a readily available and relatively low dose test to investigate and assist in clinical decision-making for patients of all ages. Furthermore, given a particular clinical concern, the abdominal X-ray is a useful adjunct in conjunction with the clinical assessment in determining which patients may require further cross-sectional imaging. In a low pre-test probability patient, this may preclude the need for further evaluation with CT, thereby reducing the patient's radiation dose.

The Royal College of Radiologists has published iRefer guidelines to assist clinicians in requesting the most appropriate imaging test for patients. These guidelines provide invaluable information, including the clinical indications that abdominal X-rays should be requested for. These include, however are not limited to: preliminary evaluation for bowel obstruction, radiopaque foreign body evaluation, evaluation of radiopaque lines and tubes and assessment for renal calculi.

Despite its universal importance, X-ray interpretation is often an overlooked subject in the medical school curriculum, making it difficult and daunting for many medical students and junior doctors. *The Unofficial Guide to Radiology: 100 Practice Abdominal X-Rays, with Full Colour Annotations and Full X-Ray Reports* aims to help address this.

The key to interpreting X-rays is having a systematic method for assessment, and then getting lots of practice looking at and presenting X-rays. The best-selling core radiology text *The Unofficial Guide to Radiology* was specifically designed for medical students, radiographers, physician's associates, and junior doctors. It outlines a comprehensive system for assessing X-rays, in additional to clinical and radiology based MCQs to contextualise the radiographs to real clinical scenarios. Its approach led to recognition from the British Medical Association, the British Institute of Radiology and the Royal College of Radiologists. This follow-up textbook builds upon these foundations, providing readers with the opportunity to practise and consolidate their abdominal X-ray assessment and presenting skills.

There are lots of radiology textbooks available, but many have important limitations. Most have small, often poor quality images which are not ideal for displaying the radiological findings. The findings are usually only described in a figure below the image, and it may be difficult to know exactly what part of the image corresponds to which finding! Many textbooks deal with X-rays in isolation rather than in a useful clinical context.

We have designed this book to allow readers to practice interpreting X-rays in as useful and clinically relevant a way as possible. There are:

- 100 large, high quality abdominal X-rays to assess.
- Cases presented in the context of a clinical scenario and covering a wide range of common and important findings (in line with the Royal College of Radiologists' Undergraduate Radiology Curriculum).
- Detailed on-image colour annotations to highlight key findings.
- Comprehensive systematic X-ray reports.
- Relevant further investigations and management.

The cases in the book are divided by difficulty into standard, intermediate and advanced. Each begins with a clinical scenario and an abdominal X-ray for you to interpret. You can then turn over the page, and find a fully annotated version of the same X-ray with a comprehensive report. Each systematically structured report is colour coded to match the corresponding labelled image.

Each report is based on a systematic approach to assessing the abdominal X-ray, and is as follows:

- Technical features
- Bowel gas pattern
- Bowel wall
- Pneumoperitoneum
- Solid organs
- Vascular
- Bones
- Soft tissues
- Other
- Review areas
- Summary
- Investigations and management

Realistic clinical history

SCENARIO 1

A 36 year old female presents to ED with a 2 day history of generalised abdominal pain. She has not opened her bowels in that time and feels nauseated but has not vomited. Her past medical history is significant for a recent toothache, for which she has been taking cocodamol and she is a non-smoker. On examination, she has saturations of 99% in room air and a temperature of 36.9°C. Her HR is 82 bpm, RR is 15 and blood pressure is 115/66 mmHg. The abdomen is distended with tenderness over the right side and voluntary guarding. Bowel sounds are normal. Urine dipstick is unremarkable and a pregnancy test is negative.

An abdominal X-ray is requested to assess for possible bowel obstruction.

Large, high quality image to assess

Detailed report following a standard format

REPORT – FAECAL RESIDUE

REPORT
Patient ID: Anonymous.
Projection: AP supine.
Rotation: Adequate.
Penetration: Adequate – the spinous processes are visible.
Coverage: Adequate – the anterior ribs are visible superiorly and the inferior pubic rami are visible.

BOWEL GAS PATTERN
The bowel gas pattern is normal.

There is moderate volume of faecal residue present predominantly from the caecum to proximal transverse colon.

BOWEL WALL
There is no evidence of mural thickening or intramural gas within the large or small bowel.

PNEUMOPERITONEUM
There is no evidence of free intra-abdominal gas.

SOLID ORGANS
The solid organ contours are within normal limits with no solid organ calcification.

VASCULAR
No abnormal vascular calcification.

BONES
There is degenerative change visible in the distal lumbar spine with osteophyte formation.

There is degenerative change in the weight-baring region of the sacroiliac joints bilaterally.

No fractures or destructive bone lesions are visible in the imaged skeleton.

SOFT TISSUES
The psoas muscle outline is visible bilaterally.

The extra-abdominal soft tissues are unremarkable.

OTHER
There are no radiopaque foreign bodies.

There are no vascular lines, drains or surgical clips.

REVIEW AREAS
Gallstones / Renal calculi: No radio-opaque calculi.
Lung bases: Not fully included.
Spine: Degenerative change in the distal lumbar spine and weight-baring sacroiliac joints.
Femoral heads: Normal.

x-ray review areas specifically highlighted

Clear annotations highlighting the major x-ray findings

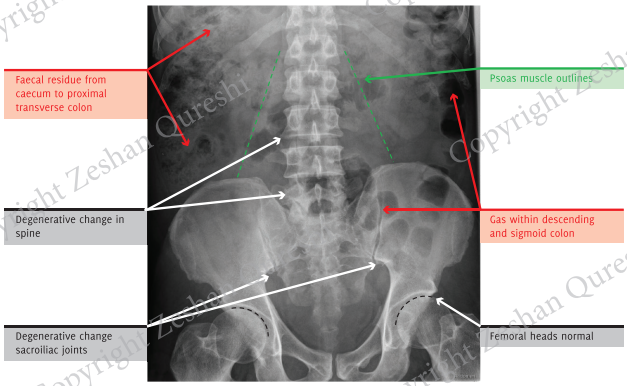

SUMMARY
This X-ray demonstrates a moderate volume of faecal residue predominantly in the ascending and proximal transverse colon. There are mild degenerative changes in the distal lumbar spine and weight-baring sacroiliac joints bilaterally. There is no evidence of bowel obstruction or pneumoperitoneum.

INVESTIGATIONS AND MANAGEMENT
If the patient is clinically constipated, current medications should be reviewed and laxatives considered. Advice should be given regarding lifestyle adjustments, including adequate fluid intake, sufficient dietary fibre and exercise if clinically appropriate.

If the patient is otherwise well, no further investigation or imaging is required.

Investigations & management plan put the x-ray in the context of the overall clinical management

With this textbook, we hope you will become more confident and competent interpreting abdominal X-rays, both in exam situations and in clinical practice.

We also hope that this is just the beginning; we want you to get involved! This textbook has been a collaboration with junior doctors and students just like you. You have the power to contribute something valuable to medicine; we welcome your suggestions and would love for you to get in touch. A good starting point is our Facebook page, which is growing into a forum for medical education.

Please get in touch and be part of the medical education project.

Daniel Weinberg

TheUnofficialGuideToMedicine

admin@unofficialguidetomedicine.com

@UGTMedicine

@UGTMedicine

The Unofficial Guide to Medicine

FOREWORD

Emma Watura

To support good quality patient care, it is important to develop a structured approach to interpreting radiological images and presenting the findings. *The Unofficial Guide to Radiology: 100 Practice Abdominal X-rays with Full Colour Annotations and Full X-Ray Reports* offers plenty of opportunity to practise image interpretation and test yourself using large, high quality images.

Each X-ray is accompanied by a realistic scenario, making it more relevant to clinical practice. A variety of cases are covered, ranging from standard to advanced level. Therefore, students can begin at a level suitable for them and progress accordingly. The summaries provided for each case are great examples of how to present X-ray findings to colleagues or examiners. In addition, useful advice is given for further investigations and management.

A systematic method for assessing and reporting abdominal X-rays is demonstrated throughout. Each report is laid out with anatomical subtitles. This is a good method to learn as it ensures all review areas are inspected. The X-rays are clearly annotated with concise notes and a colour code, making *The Unofficial Guide to Radiology* easy to read and appealing to medical students, junior doctors and other healthcare professionals.

I would recommend this textbook to anyone hoping to enhance their knowledge and competence in interpreting abdominal X-rays. I look forward to referring to *The Unofficial Guide to Radiology* more often in the future to improve my confidence in radiological image interpretation.

EMMA WATURA
Medical Student, The University of Birmingham, UK
Medical Student Representative, The Society of Radiologists in Training

Vikas Shah

The investigation of abdominal disease is evolving rapidly, and with imaging modalities such as CT and MRI being more easily accessible, the role of the plain film radiography has declined in recent years. However, the abdominal x-ray (AXR) is still a widely utilised test. The interpretation of AXRs, like most other plain films in the acute setting, falls primarily to junior doctors. The AXR is one of the toughest imaging tests to interpret accurately due to the multiple overlapping structures of varying density within a complex 3-dimensional compartment, displayed as a 2-dimensional image. However, despite the decline of the AXR, it remains an important and valuable tool and a working knowledge of correct interpretation can only have positive benefits for patient outcomes.

There are several aspects of this textbook that will make it essential reading for multiple different professional groups. Rather than focussing purely on the x-ray findings, the authors have provided valuable clinical context by offering some history and examination findings, and ending each case with a summary and suggestions on the next investigative and management steps. This approach will be particularly useful for medical students and junior doctors. An important facet of any radiology book is high-resolution images, found in abundance here. The accompanying annotated images with the key findings listed in a systematic manner ensures a consistent format running throughout the book. There is ample coverage of the common abnormalities encountered, as well as those that are less common but important not to miss.

The authors are to be commended for producing an easily digestible, visually pleasing and methodically structured book, providing plentiful material to enable more confident interpretation of the AXR. Undergraduates, qualified doctors, physician associates and radiographers will all have something to take away from this book, and I am delighted to give it my full endorsement.

VIKAS SHAH
Consultant Radiologist
University Hospitals of Leicester

ABBREVIATIONS

AAA	abdominal aortic aneurysm
ACE	Antegrade colonic enema
AP supine	anteriorposterior supine
AXR	abdominal x ray
BPM	beats per minute
CMV	cytomegalovirus
COPD	chronic obstructive pulmonary disease
CRP	c-reactive protein
CT scan	computerised tomography scan
CXR	chest x ray
EBV	ebstein-barr virus
ECG	electrocardiogram
ED	emergency department
ESR	erythrocyte sedimentation rate
ET tube	endotracheal tube
FBC	full blood count
FISH	florescence in situ hybridisation
GCS	Glasgow coma scale
GP	general practitioner
HR	heart rate
IUCD	intrauterine contraceptive device
IV	intravenous
IVC	inferior vena cava
LFT	liver function tests
MDT	multidisciplinary team
MRI	magnetic resonance imaging
NBM	nil by mouth
NG	Nasogastric
NICU	neonatal intensive care unit
PCR	polymerase chain reaction
PEG	percutaneous endoscopic gastrostomy
PEG-J	percutaneous endoscopic transgastric jejunostomy
PR	rectal exam
RIG	radiologically inserted gastrostomy tube
RR	respiratory rate
SCBU	special care baby unit
SSRI	selective serotonin reuptake inhibitor
TFT	thyroid function tests
U and E	urea and electrolytes
USS	ultrasound scan
VP	ventriculoperitoneal

CONTRIBUTORS

AUTHORS

Daniel Weinberg
MBChB (Hons) MPhil
Radiology Registrar
Central Manchester NHS Foundation Trust

Rebecca Best
BSc (Hons) MBBCh
Academic Foundation Doctor
Queen Elizabeth University Hospital, Glasgow, UK

Lydia Shackshaft
Medical Student
Kings College Hospital, UK


Daniel Weinberg


Rebecca Best


Lydia Shackshaft

EDITORS

Mark Rodrigues
BSc (Hons) MBChB (Hons) FRCR
Radiology Registrar, Edinburgh Royal Infirmary, Edinburgh, UK

Zeshan Qureshi
BM BSc (Hons) MSc BM MRCPCH FAcadMEd MRCPS(Glasg)
Paediatric Registrar, King's College Hospital, London UK.


M. Rodrigues


Z. Qureshi

STUDENT REVIEWERS

Lydia Wilson University of Birmingham, UK

Triya Chakravorty University of Oxford, UK

SENIOR REVIEWERS

Professor Sathi Sukumar Consultant Radiologist, Central Manchester NHS Foundation Trust, UK

Dr Haider Alwan-Walker Consultant Radiologist, Central Manchester NHS Foundation Trust, UK

Dr Velauthan Rudralingam Consultant Radiologist, Central Manchester NHS Foundation Trust, UK

Dr Sue Liong Consultant Radiologist, Central Manchester NHS Foundation Trust, UK

Dr Matt Wood Obstetrics and Gynaecology Registrar, West Midlands Deanery, UK

Dr Patrice Eastwood Paediatric Surgical Registrar, Royal Belfast Hospital for Sick Children, Belfast, UK

Dr Greta McLachlan Surgical Registrar, Frimley Park Hospital, UK

Dr Christopher Gee Consultant Orthopaedic and Trauma Surgeon, NHS Lanarkshire, UK

Dr Patrick Byrne Consultant Physician & GP, Belford Hospital, Fort William, UK

CONTENTS

STANDARD

SCENARIO 1

A 36 year old female presents to ED with a 2 day history of generalised abdominal pain. She has not opened her bowels in that time and feels nauseated but has not vomited. Her past medical history is significant for a recent toothache, for which she has been taking cocodamol and she is a non-smoker. On examination, she has saturations of 99% in room air and a temperature of 36.9°C. Her HR is 82 bpm, RR is 15 and blood pressure is 115/66 mmHg. The abdomen is distended with tenderness over the right side. Bowel sounds are normal. Urine dipstick is unremarkable and a pregnancy test is negative.

An abdominal X-ray is requested to assess for possible bowel obstruction.

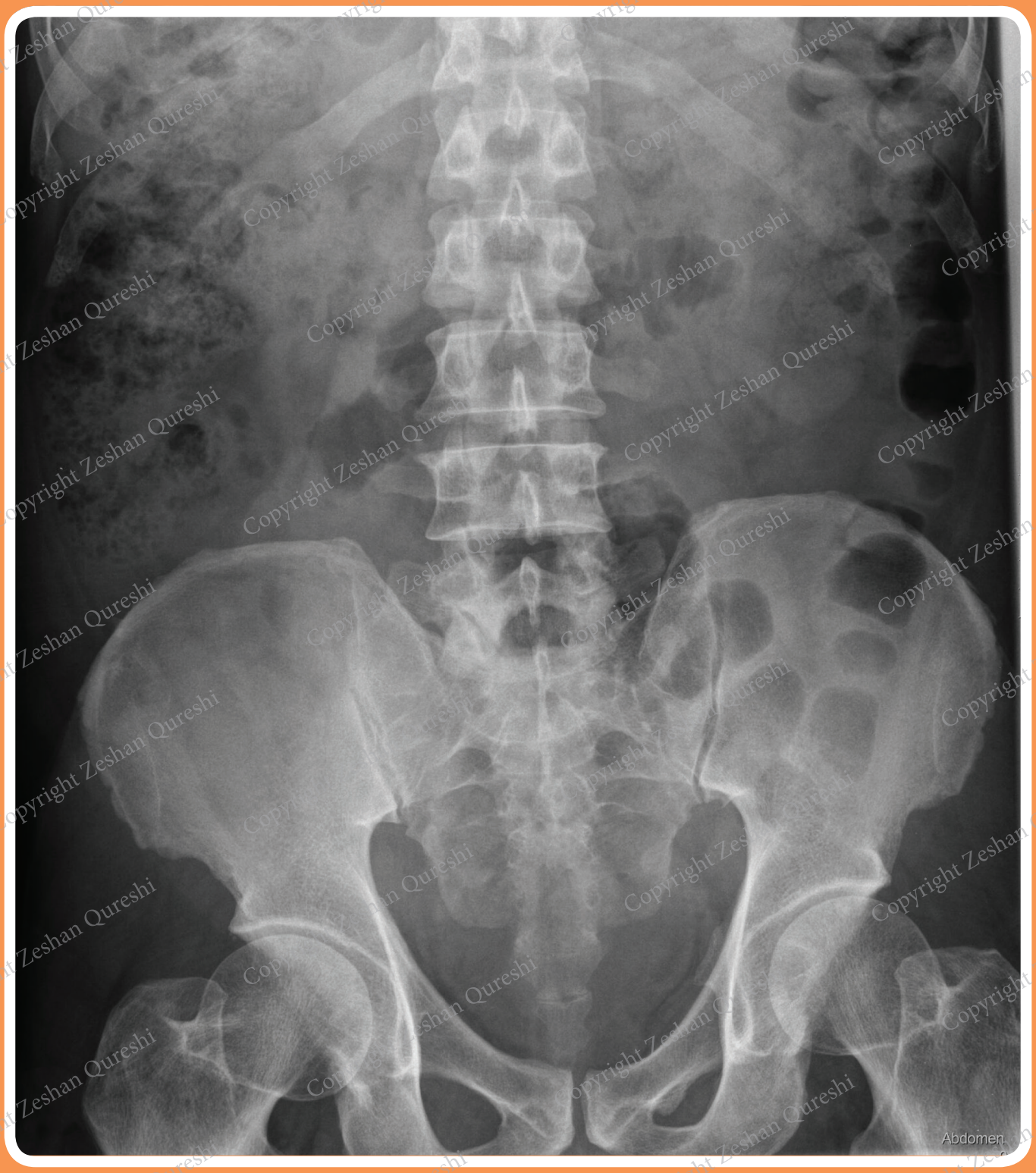

REPORT

Patient ID: Anonymous.
Projection: AP supine.
Rotation: Adequate.
Penetration: Adequate – the spinous processes are visible.
Coverage: Inadequate - the upper abdomen is not fully included.

BOWEL GAS PATTERN

The bowel gas pattern is normal.

There is moderate volume of faecal residue present predominantly from the caecum to the proximal transverse colon.

BOWEL WALL

There is no evidence of mural thickening or intramural gas within the large or small bowel.

PNEUMOPERITONEUM

There is no evidence of free intra-abdominal gas.

SOLID ORGANS

The solid organ contours are within normal limits with no solid organ calcification.

VASCULAR

No abnormal vascular calcification.

BONES

There is degenerative change visible in the distal lumbar spine with osteophyte formation.

There is degenerative change in the weight-bearing region of the sacroiliac joints bilaterally.

No fractures or destructive bone lesions are visible in the imaged skeleton.

SOFT TISSUES

The psoas muscle outline is visible bilaterally.

The extra-abdominal soft tissues are unremarkable.

OTHER

There are no radiopaque foreign bodies.

There are no vascular lines, drains or surgical clips.

REVIEW AREAS

Gallstones / Renal calculi: No radiopaque calculi.
Lung bases: Not fully included.
Spine: Degenerative change in the distal lumbar spine and weight-bearing sacroiliac joints.
Femoral heads: Normal.

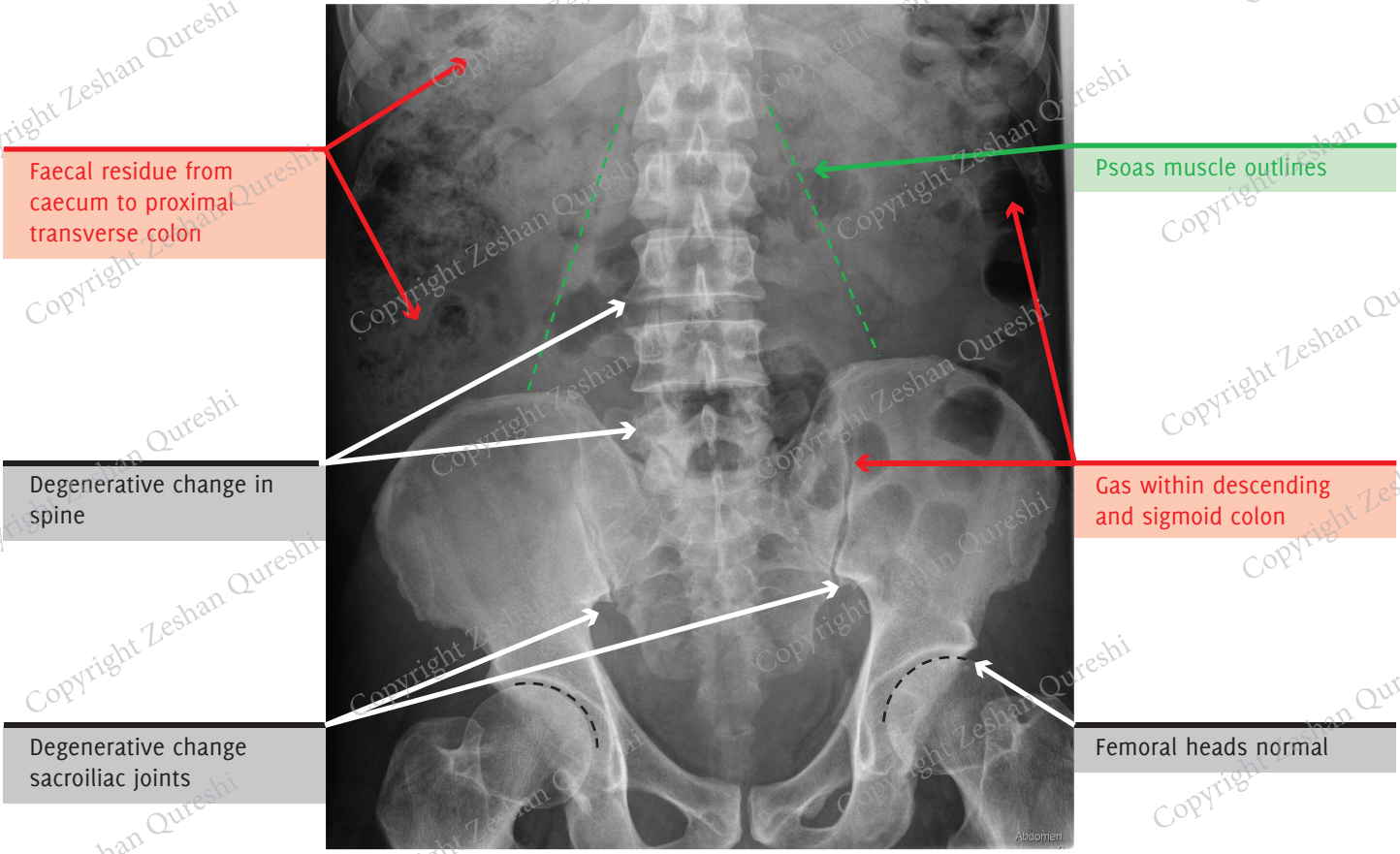

SUMMARY

This X-ray demonstrates a moderate volume of faecal residue predominantly in the ascending and proximal transverse colon. There are mild degenerative changes in the distal lumbar spine and weight-bearing sacroiliac joints bilaterally. There is no evidence of bowel obstruction or pneumoperitoneum.

INVESTIGATIONS AND MANAGEMENT

If the patient is clinically constipated, current medications should be reviewed and laxatives considered. Advice should be given regarding lifestyle adjustments, including adequate fluid intake, sufficient dietary fibre and exercise if clinically appropriate.

If the patient is otherwise well, no further investigation or imaging is required.

SCENARIO 6

A 69 year old female presents to ED with worsening abdominal distension. She has not opened her bowels for the past 48 hours. Her past medical history is significant for a previous hysterectomy 10 years ago for endometrial cancer and she is a non-smoker. On examination, she has saturations of 96% in room air and a temperature of 37.6°C. Her HR is 102 bpm, RR is 30 and blood pressure is 110/65 mmHg. The abdomen is rigid and there is generalised tenderness with tinkling bowel sounds. Urine dipstick is unremarkable.

An abdominal X-ray is requested to assess for possible bowel obstruction.

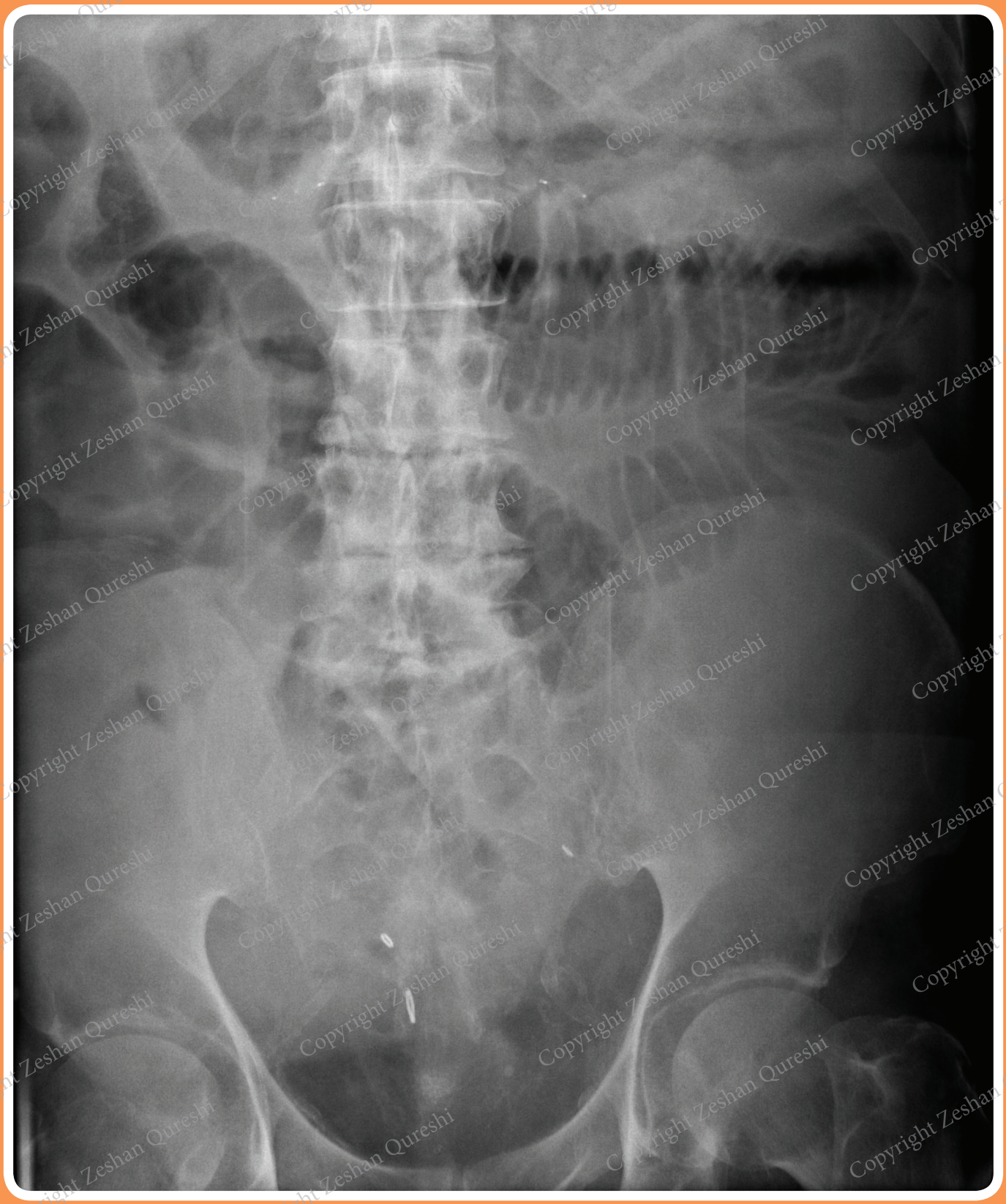

REPORT

Patient ID: Anonymous.
Projection: AP supine.
Rotation: Adequate.
Penetration: Adequate – the spinous processes are visible.
Coverage: Inadequate – the pubic symphysis, right flank and upper abdomen have not been fully included.

BOWEL GAS PATTERN

There are multiple loops of dilated bowel seen centrally in the abdomen, which demonstrate valvulae conniventes in keeping with small bowel obstruction.

BOWEL WALL

There is no evidence of mural thickening or intramural gas within the large or small bowel.

PNEUMOPERITONEUM

There is no evidence of free intra-abdominal gas.

SOLID ORGANS

The solid organ contours are within normal limits with no solid organ calcification.

VASCULAR

There is calcification of the iliac arteries bilaterally.

BONES

There is moderate degenerative change in the lower lumbar spine with osteophyte formation and intervertebral disc space narrowing.

SOFT TISSUES

The psoas muscle outline is not visible bilaterally, which is non-specific.

The extra-abdominal soft tissues are unremarkable.

OTHER

There are three radiopaque densities projected over the pelvis that appear to be surgical clips, in keeping with previous gynaecological surgery.

There are no vascular lines or drains.

REVIEW AREAS

Gallstones / Renal calculi: No radiopaque calculi.
Lung bases: Not fully included.
Spine: Moderate degenerative change in lower lumbar spine.
Femoral heads: Normal.

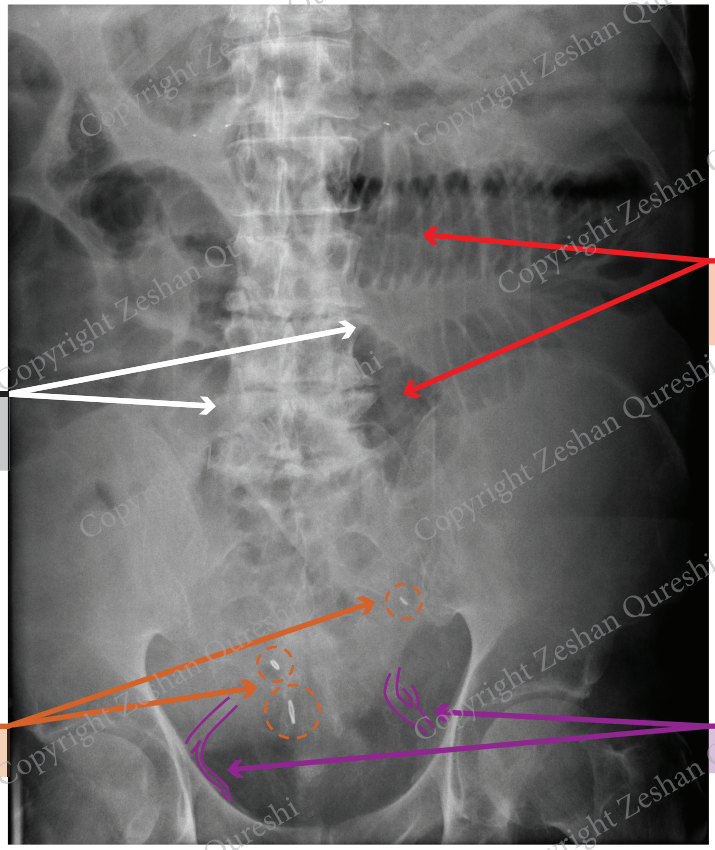

SUMMARY

This X-ray demonstrates multiple loops of dilated bowel seen centrally within the abdomen demonstrating valvulae conniventes, in keeping with small bowel obstruction. No cause for this is visible, however, given the clinical history, this is likely secondary to adhesions from previous surgery. The bilateral iliac artery calcifications, moderate degenerative changes in the lower lumbar spine and pelvic surgical clips are incidental findings.

INVESTIGATIONS AND MANAGEMENT

The patient should be resuscitated using an ABCDE approach.

Adequate analgesia and hydration should be provided.

The patient should be kept NBM and an NG tube inserted on free drainage to relieve the pressure in the small bowel. IV fluids should be commenced.

Urgent bloods should be taken, including FBC, U&Es, CRP, LFTs, coagulation, blood gas, and group and save.

The general surgical team should be contacted urgently and a CT scan of the abdomen/pelvis with IV contrast should be considered for better visualisation of the anatomy and further assessment.

SCENARIO 10

A 30 year old male presents to ED with left sided loin pain radiating to the left groin. His past medical history is significant for previous renal calculi and he is a non-smoker. He has previously had a left-sided ureteric stent inserted. On examination, he has saturations of 96% in room air and a temperature of 36.8°C. His HR is 102 bpm, RR is 24 and blood pressure is 130/80 mmHg. The abdomen is soft with tenderness in the left loin radiating to the left groin. Bowel sounds are normal. Urine dipstick shows blood +++.

An abdominal X-ray is requested to assess for possible renal calculi.

REPORT
Patient ID: Anonymous.
Projection: AP supine.
Rotation: Adequate.
Penetration: Adequate – the spinous processes are visible.
Coverage: Inadequate – the inferior pubic rami have not been fully included.

BOWEL GAS PATTERN
The bowel gas pattern is normal.

There is a mild volume of faecal residue present throughout the ascending colon.

BOWEL WALL
There is no evidence of mural thickening or intramural gas within the large or small bowel.

PNEUMOPERITONEUM
There is no evidence of free intra-abdominal gas.

SOLID ORGANS
There are 2 small radiopaque densities projected over the region of the inferior pole of the left kidney, in keeping with renal calculi.

VASCULAR
No abnormal vascular calcification.

BONES
There are no abnormalities of the imaged thoracic and lumbar spine, or within the pelvis.

SOFT TISSUES
The psoas muscle outline is visible bilaterally.

The extra-abdominal soft tissues are unremarkable.

OTHER
There is a radiopaque line projected over the region of the left ureter, which represents a correctly sited JJ ureteric stent.

There are several radiopaque densities projected to the left side of the ureteric stent at the level of L3/4, in keeping with ureteri calculi.

There are no vascular lines, drains or surgical clips.

REVIEW AREAS
Gallstones / Renal calculi: Renal calculi in inferior pole of left kidney and left ureter.
Lung bases: Not fully included.
Spine: Normal.
Femoral heads: Normal.

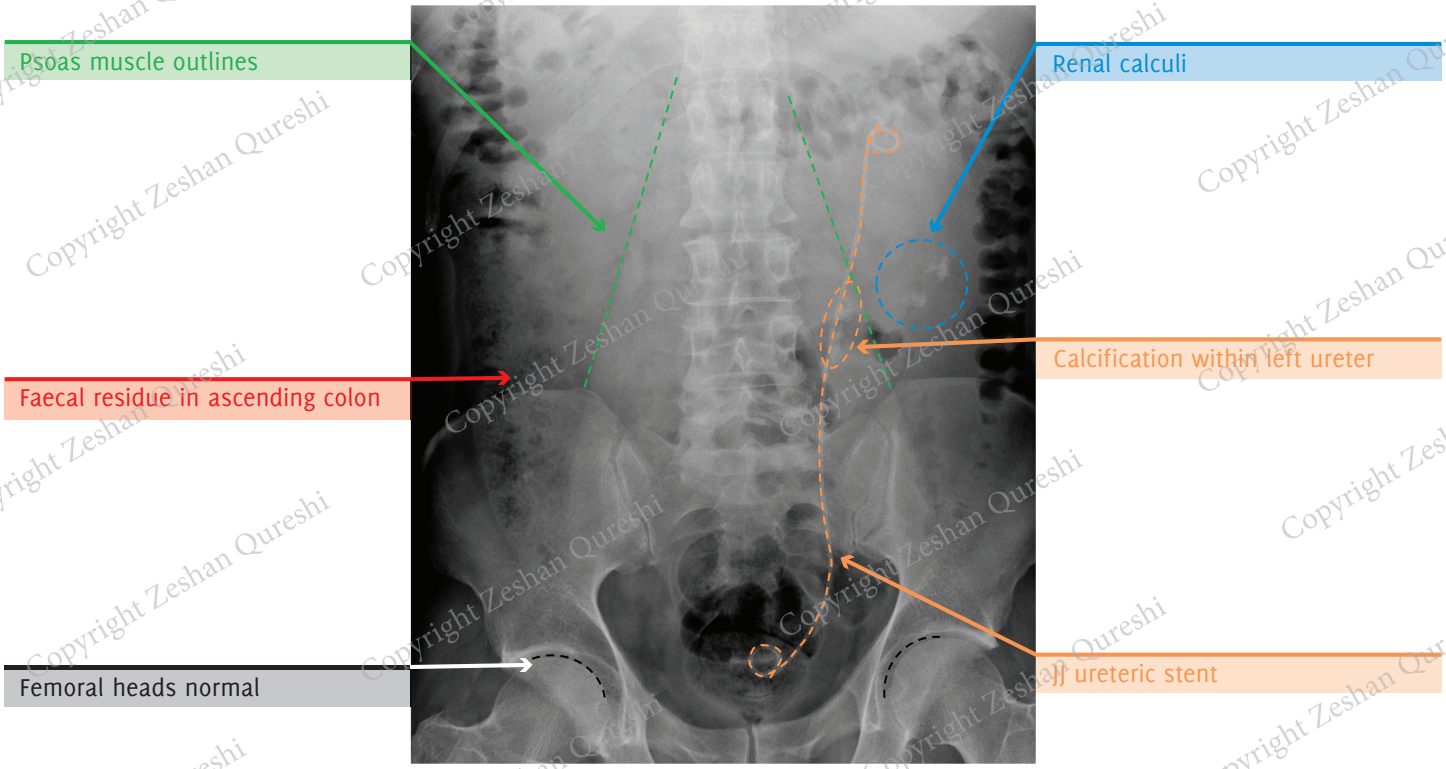

SUMMARY
This X-ray demonstrates 2 small radiopaque densities projected over the region of the inferior pole of the left kidney, in keeping with renal calculi. It also demonstrates a left-sided JJ ureteric stent in situ with associated ureteric calculi. There is a mild volume of faecal residue within the ascending colon.

INVESTIGATIONS AND MANAGEMENT
The patient should be resuscitated using an ABCDE approach.

Adequate analgesia and hydration should be provided.

Urgent bloods should be taken, including FBC, U&Es, CRP, LFTs, blood gas, and bone profile.

The patient should be assessed for acute kidney injury, and if present, an ultrasound of the urinary tract in the first instance would be beneficial in assessing for hydronephrosis.

Smaller stones may pass spontaneously, but referral to urology is required for possible further intervention. A CT scan of the kidneys, ureters and bladder might be useful for better visualisation of the anatomy.

SCENARIO 15

A 45 year old male presents to ED with worsening abdominal distension. He has not passed flatus or opened his bowels for over 48 hours. He has no significant past medical history. On examination, he has saturations of 97% in room air and a temperature of 37.6°C. His HR is 94 bpm, RR is 20 and blood pressure is 134/92 mmHg. The abdomen is rigid and there is generalised tenderness with tinkling bowel sounds. Urine dipstick is unremarkable.

An abdominal X-ray is requested to assess for possible bowel obstruction.

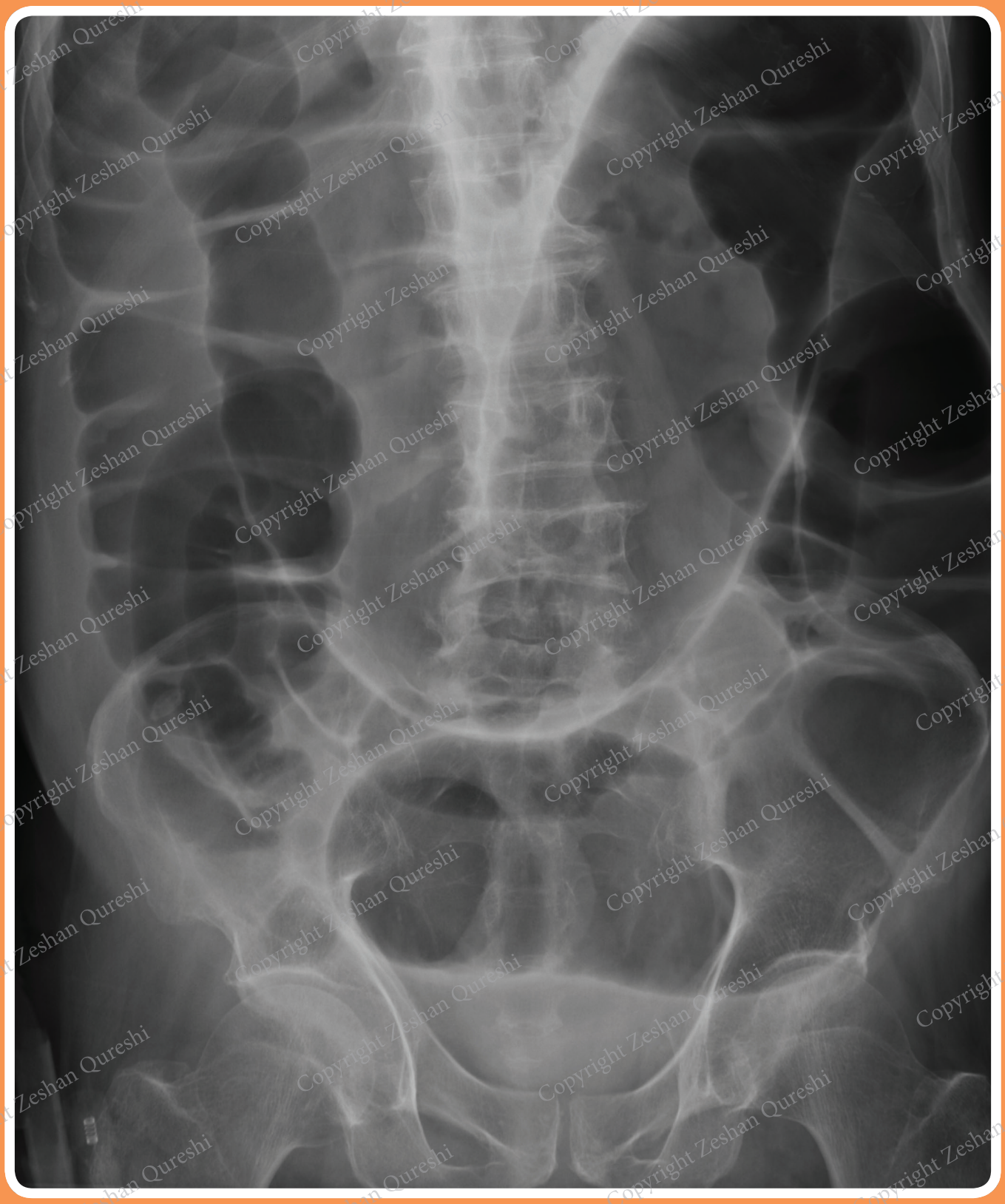

REPORT

Patient ID: Anonymous.
Projection: AP supine.
Rotation: Adequate.
Penetration: Adequate – the spinous processes are visible.
Coverage: Inadequate – the anterior ribs have not been included.

BOWEL GAS PATTERN

There are multiple loops of dilated bowel seen in the abdomen demonstrating haustra, in keeping with large bowel obstruction. A dilated small bowel loop is visible in the right lower quadrant.

Bowel gas is not seen in the rectum.

BOWEL WALL

There is no evidence of mural thickening or intramural gas within the large or small bowel.

PNEUMOPERITONEUM

There is no evidence of free intra-abdominal gas.

SOLID ORGANS

The solid organ contours are within normal limits with no solid organ calcification.

VASCULAR

No abnormal vascular calcification.

BONES

There are degenerative changes in the lumbar spine with lateral osteophytes at L1/2 and a mild scoliosis convex to the left at L4/L5. The L3 and L4 vertebral bodies have reduced height with concave endplates, in keeping with endplate fractures of indeterminate age.

SOFT TISSUES

The psoas muscle outline is visible bilaterally.

The extra-abdominal soft tissues are unremarkable.

OTHER

There are no radiopaque foreign bodies.

There are no vascular lines, drains or surgical clips.

REVIEW AREAS

Gallstones / Renal calculi: No radiopaque calculi.
Lung bases: Not fully included.
Spine: Degenerative changes and endplate fractures as described.
Femoral heads: Normal.

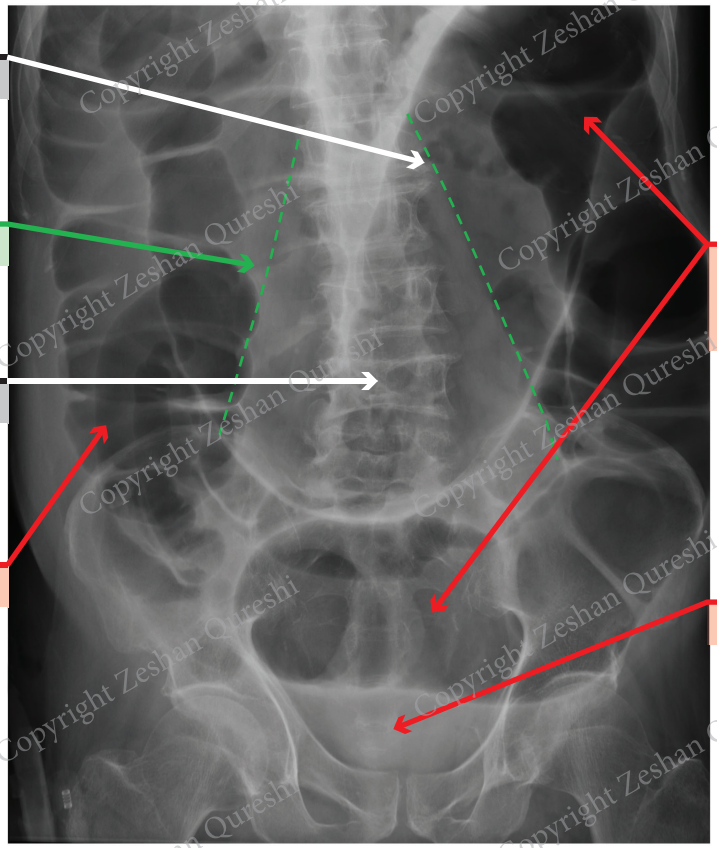

SUMMARY

This X-ray demonstrates multiple loops of dilated bowel seen within the abdomen demonstrating haustra, in keeping with large bowel obstruction, as well as a loop of dilated small bowel. The absence of gas in the small intestine indicates a competent ileo-caecal valve creating a closed-loop obstruction. The absence of bowel gas in the rectum suggests a distal obstructing point. Given the absence of previous abdominal or pelvic surgery, findings may be secondary to a benign or malignant stricture. Vertebral endplate fractures of indeterminate age are also noted, which may be related to malignancy.

INVESTIGATIONS AND MANAGEMENT

The patient should be resuscitated using an ABCDE approach. Adequate analgesia and hydration should be provided.

The patient should be kept NBM and an NG tube inserted on free drainage. IV fluids should be commenced.

Urgent bloods should be taken, including FBC, U&Es, CRP, LFTs, coagulation, blood gas, and group and save.

The general surgical team should be contacted urgently and a CT scan of the abdomen/pelvis with IV contrast should be considered for better visualisation of the anatomy and further assessment. With regard to the bony changes, further history should be taken, and previous images reviewed.

SCENARIO 26

A 13 month old boy presents to ED with worsening abdominal pain and a 2 day history of diarrhoea and vomiting. He has no significant past medical history. On examination, he has saturations of 98% in room air and a temperature of 38.3°C. His HR is 150 bpm and RR is 35. The abdomen is soft and there is generalised tenderness with normal bowel sounds. Urine dipstick is unremarkable.

An abdominal X-ray is requested to assess for possible bowel obstruction.

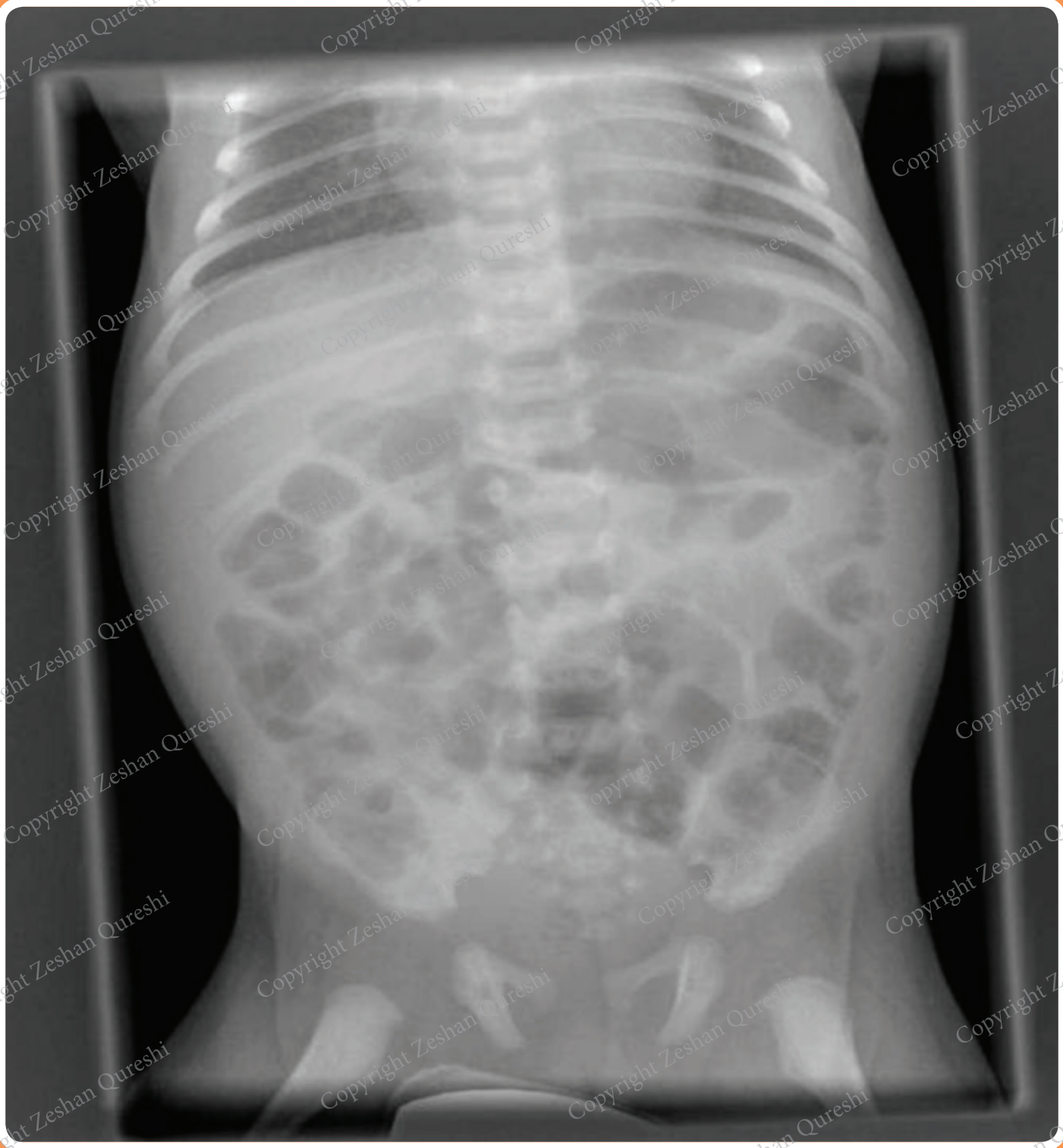

REPORT

Patient ID: Anonymous.
Projection: AP supine.
Rotation: Adequate.
Penetration: Adequate – the spine is visible.
Coverage: Adequate – the anterior ribs are visible superiorly and the inferior pubic rami are visible.

BOWEL GAS PATTERN

The bowel gas pattern is normal.

BOWEL WALL

There is no evidence of mural thickening or intramural gas within the large or small bowel.

PNEUMOPERITONEUM

There is no evidence of free intra-abdominal gas.

SOLID ORGANS

The solid organ contours are within normal limits with no solid organ calcification.

VASCULAR

No abnormal vascular calcification.

BONES

There are no abnormalities of the imaged thoracic and lumbar spine, or within the pelvis.

SOFT TISSUES

The psoas muscle outline is not visible bilaterally, which is non-specific, particularly in a child of this age.

The extra-abdominal soft tissues are unremarkable.

OTHER

There is a gonadal shield in situ.

There are no vascular lines, drains or surgical clips.

REVIEW AREAS

Gallstones / Renal calculi: No radiopaque calculi.
Lung bases: Normal.
Spine: Normal – cartilage between vertebrae.
Femoral heads: Normal – growth plates present.

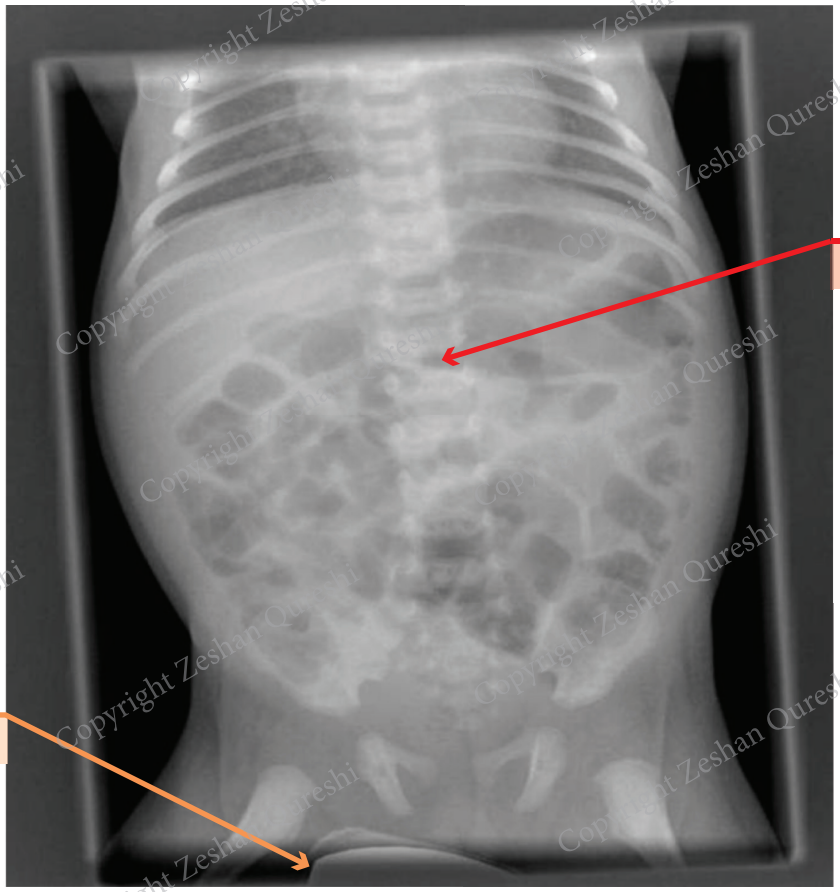

SUMMARY

This X-ray demonstrates a normal abdominal appearance with no evidence of bowel obstruction.

INVESTIGATIONS AND MANAGEMENT

The child should be resuscitated using an ABCDE approach.

Adequate analgesia and hydration should be provided.

Urgent bloods should be taken, including FBC, U&Es, CRP, and blood gas.

The most likely diagnosis is gastroenteritis, given the pyrexia, that the child is otherwise well, and the history of diarrhoea and vomiting. Treatment for this would include rehydration (either orally, by NG tube or by IV fluids depending on the clinical picture) and management of the pyrexia if symptomatic.

INTERMEDIATE

SCENARIO 36

A 24 year old male presents to ED with worsening abdominal pain and 15 episodes of diarrhoea and passing mucus in the past 24 hours. He has no significant past medical history and is a non-smoker. On examination, he has saturations of 97% in room air and a temperature of 38.5°C. His HR is 94 bpm, RR is 22 and blood pressure is 115/65 mmHg. The abdomen is rigid and there is generalised tenderness with normal bowel sounds. Urine dipstick is unremarkable.

An abdominal X-ray is requested to assess for a possible colitis.

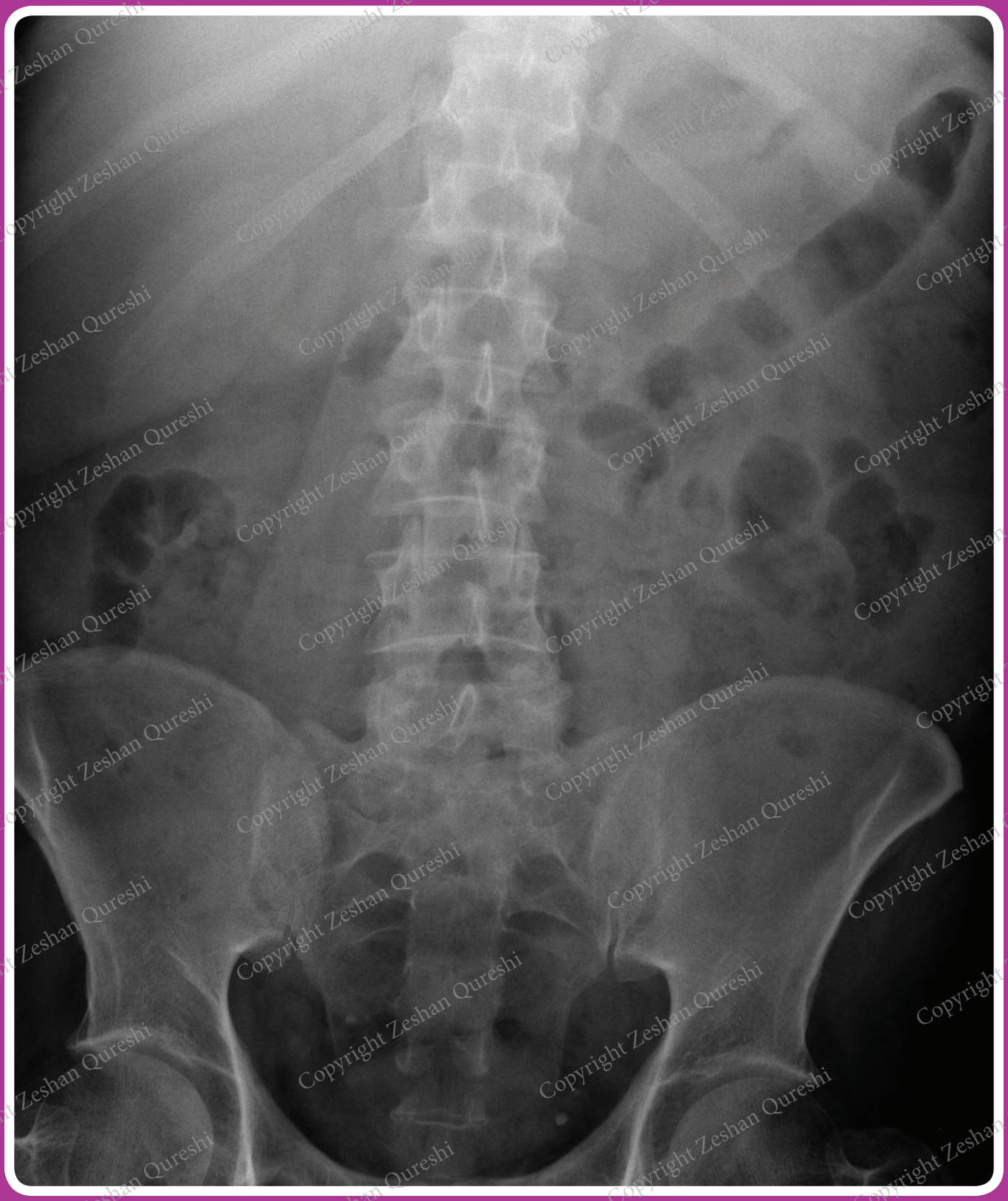

REPORT

Patient ID: Anonymous.
Projection: AP supine.
Rotation: Adequate.
Penetration: Adequate – the spinous processes are visible.
Coverage: Inadequate – the pubic symphysis and inferior pubic rami have not been fully included.

BOWEL GAS PATTERN

The bowel gas pattern is normal.

BOWEL WALL

There is mural thickening of the distal transverse colon up to the splenic flexure in the left upper quadrant, which appears featureless with loss of the normal colonic haustral folds, in keeping with mural oedema. This is termed 'lead pipe colon'.

There is no evidence of intramural gas within the large or small bowel.

PNEUMOPERITONEUM

There is no evidence of free intra-abdominal gas.

SOLID ORGANS

The solid organ contours are within normal limits with no solid organ calcification.

VASCULAR

No abnormal vascular calcification.

BONES

There are no abnormalities of the imaged thoracic and lumbar spine, or within the pelvis.

SOFT TISSUES

The psoas muscle outline is visible bilaterally.

The extra-abdominal soft tissues are unremarkable.

OTHER

There are no radiopaque foreign bodies.

There are no vascular lines, drains or surgical clips.

There are several rounded radiopaque densities projected over the region of the pelvis in keeping with phleboliths.

REVIEW AREAS

Gallstones / Renal calculi: No radiopaque calculi.
Lung bases: Not fully included.
Spine: Normal.
Femoral heads: Normal.

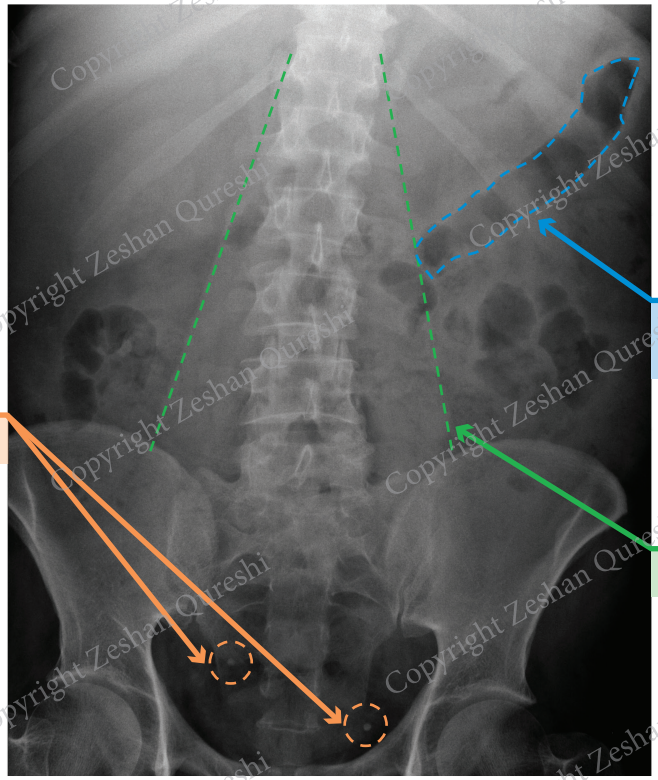

SUMMARY

This X-ray demonstrates mural oedema of the distal transverse colon up to the splenic flexure, which appears featureless with loss of the normal colonic haustral folds. Given the clinical history, this is suggestive of colitis, likely infective or inflammatory in nature. The pelvic phleboliths are an incidental finding.

INVESTIGATIONS AND MANAGEMENT

This patient should be resuscitated using an ABCDE approach.

Adequate analgesia and hydration should be provided.

Urgent bloods should be taken, including FBC, U&Es, LFTs, ESR, CRP, iron studies, folate, blood gas, and group and save. A stool sample should be sent.

Urgent referral to the gastroenterology team should be considered.

A CT scan of the abdomen/pelvis with IV contrast should be considered for better visualisation of the anatomy and to assess for complications such as pneumoperitoneum and abscess formation.

Treatment will depend on the results of further investigations, as well as the clinical state of the patient.

SCENARIO 42

A 3 day old baby boy, currently admitted on SCBU, is acutely unwell and deteriorating rapidly. He was born prematurely at 32 weeks but has been progressing well up until this point. On examination, he has saturations of 96% in room air and a temperature of 38.5°C. His HR is 245 bpm and RR is 68. The abdomen is rigid with tinkling bowel sounds.

An abdominal X-ray is requested to assess for possible necrotising enterocolitis.

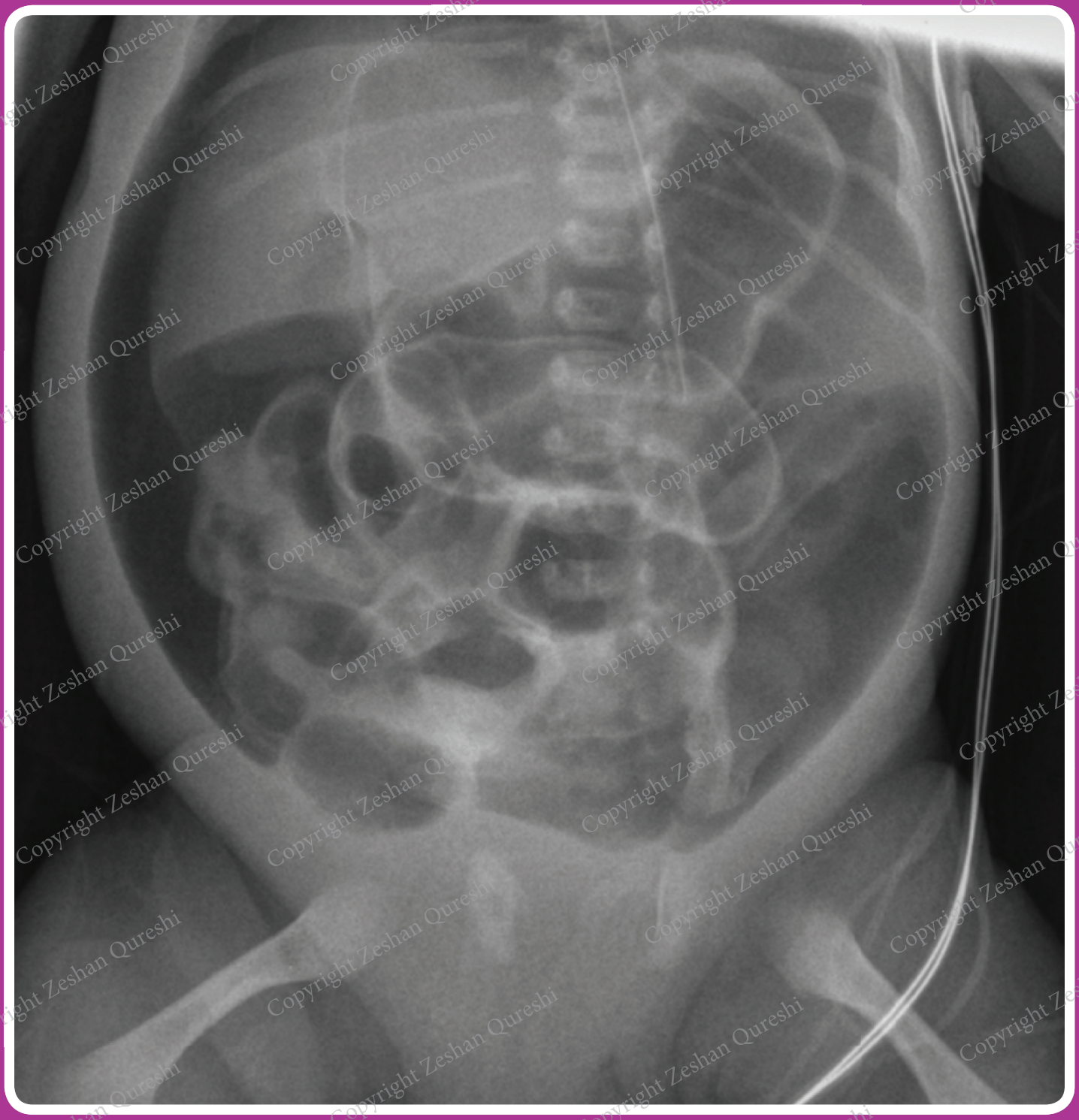

REPORT

Patient ID: Anonymous.
Projection: AP supine.
Rotation: Asymmetrical appearances of the pelvis with deviation of the spine to the left in keeping with patient rotation to the right.
Penetration: Adequate – the spine is visible.
Coverage: Inadequate –the hemidiaphragms have not been included.

BOWEL GAS PATTERN

There are multiple loops of dilated bowel seen centrally within the abdomen. There is no gas within the rectum.

BOWEL WALL

There is no evidence of mural thickening or intramural gas within the large or small bowel.

PNEUMOPERITONEUM

There is evidence of free intra-abdominal gas, in keeping with pneumoperitoneum.

Rigler's sign (double wall sign) can be seen, in keeping with air present on both the luminal and peritoneal sides of the bowel wall.

The falciform ligament sign can be seen, in keeping with a large amount of air present within the abdomen outlining the falciform ligament.

The football sign can be seen, in keeping with a large amount of air present within the abdomen outlining the entire abdominal cavity.

SOLID ORGANS

The liver and falciform ligament are well-outlined by free gas in the abdomen.

VASCULAR

No abnormal vascular calcification.

BONES

There are no abnormalities of the imaged thoracic and lumbar spine, or within the pelvis.

There is cartilage present between the pelvic bones and femurs as they have not yet fused, which is a normal finding in a child of this age.

There is cartilage seen between the vertebrae, which is a normal finding in a child of this age.

SOFT TISSUES

The psoas muscle outline is not seen bilaterally, which is non-specific, particularly in a child of this age.

The extra-abdominal soft tissues are unremarkable.

OTHER

There is an NG tube in situ, although given how straight it is, there is a possibility it has perforated the oesophagus.

There is an electrode and lead external to the patient on the left, in keeping with cardiopulmonary monitoring.

There are no vascular lines, drains or surgical clips.

REVIEW AREAS

Gallstones / Renal calculi: No radiopaque calculi.
Lung bases: Not fully included.
Spine: Normal – cartilage between vertebrae.
Femoral heads: Normal – growth plates present.

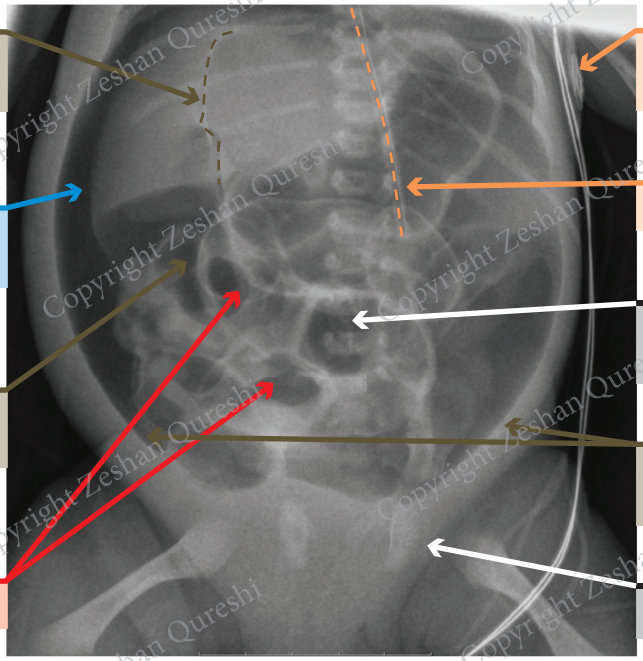

SUMMARY

This X-ray demonstrates multiple loops of dilated bowel throughout the abdomen with evidence of pneumoperitoneum. There is no gas within the rectum. Given the clinical history, the most likely diagnosis is bowel perforation, which may be due to necrotising enterocolitis. The NG tube should be checked to ensure there is a gastric aspirate.

INVESTIGATIONS AND MANAGEMENT

The baby should be resuscitated using an ABCDE approach.

The baby should be started on broad spectrum antibiotics, made NBM and started on IV fluids.

The baby needs to be intubated given the perforation.

Urgent bloods should be taken, including FBC, U&Es, CRP, bone profile, LFTs, coagulation, blood cultures, blood gas, and group and save. A lateral shoot-through AXR would be helpful to confirm perforation, and NG position.

The patient should be referred urgently to the neonatal surgeons for ongoing management.

SCENARIO 51

A 75 year old female presents to ED with worsening bone pain and abdominal pain, having not opened her bowels for 5 days. Her past medical history is significant for renal cell carcinoma (awaiting surgery) and she is a non-smoker. On examination, she has saturations of 95% in room air and a temperature of 37.1°C. Her HR is 88 bpm, RR is 19 and blood pressure is 130/75 mmHg. The abdomen is soft and non-tender with normal bowel sounds. Urine dipstick is unremarkable.

An abdominal X-ray is requested to assess for possible bowel obstruction.

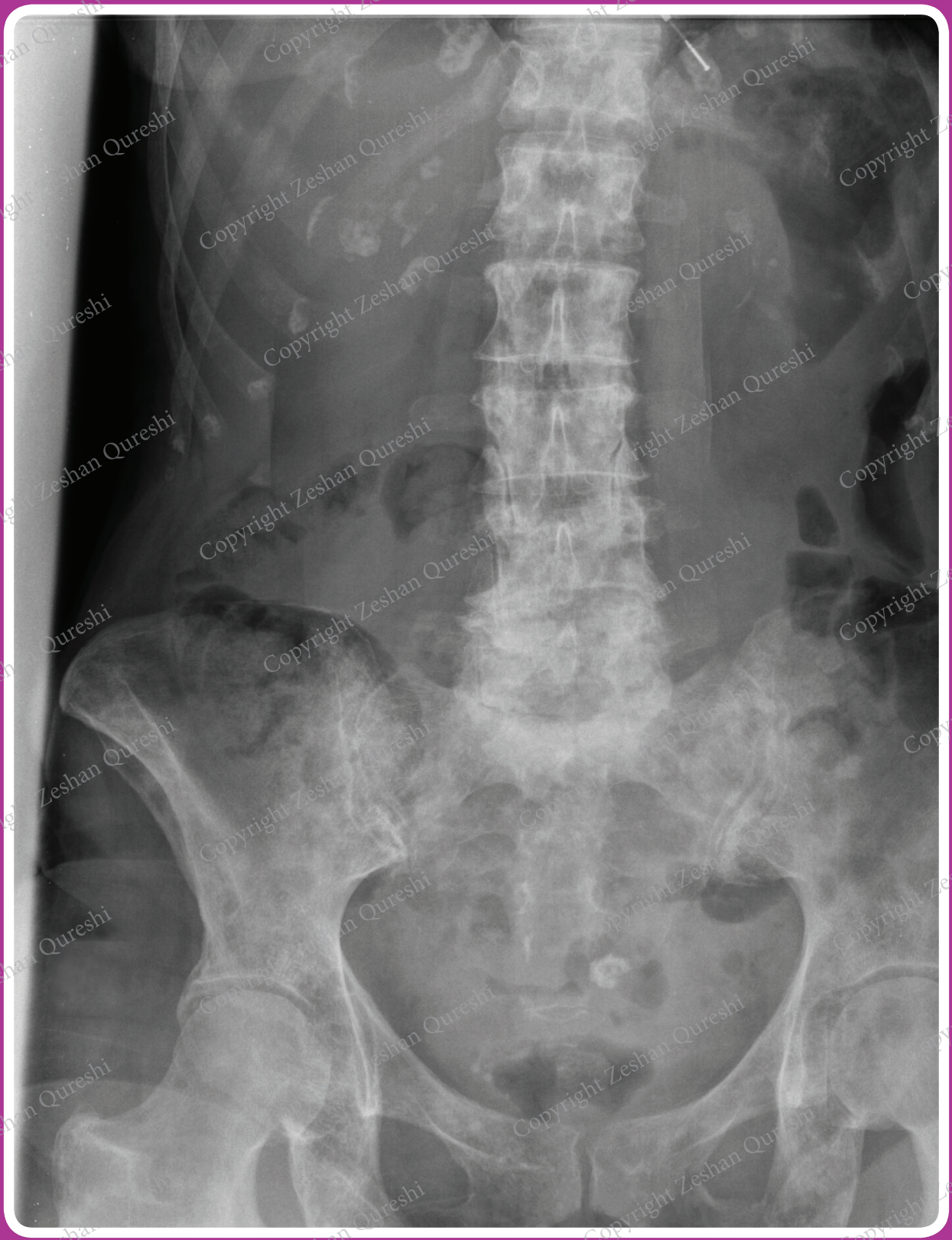

REPORT
Patient ID: Anonymous.
Projection: AP supine.
Rotation: Adequate.
Penetration: Adequate – the spinous processes are visible.
Coverage: Inadequate – the lateral aspect of the left ilium and inferior pubic rami have not been included.

BOWEL GAS PATTERN
There is mild volume of faecal residue predominantly in the ascending colon.

BOWEL WALL
There is no evidence of mural thickening or intramural gas within the large or small bowel.

PNEUMOPERITONEUM
There is no evidence of free intra-abdominal gas.

SOLID ORGANS
The solid organ contours are within normal limits with no solid organ calcification.

VASCULAR
No abnormal vascular calcification.

BONES
There are multiple mixed lytic/sclerotic bone lesions throughout the axial skeleton, including in the spine and the pelvis bilaterally.

There are moderate degenerative changes in the distal lumbar spine.

There is bilateral costochondral calcification.

SOFT TISSUES
The psoas muscle outline is visible bilaterally.

The extra-abdominal soft tissues are unremarkable.

OTHER
There is a cardiac pacing lead projecting to the left of the T12 vertebral body likely within the right ventricle.

There is an area of calcification projecting within the pelvis likely to represent mesenteric lymph node calcification.

There are no vascular lines, drains or surgical clips.

REVIEW AREAS
Gallstones / Renal calculi: No radiopaque calculi.
Lung bases: Not fully included.
Spine: Mixed lytic/sclerotic spinal lesions with moderate degenerative changes in the distal lumbar spine.
Femoral heads: Multiple lytic bone lesions.

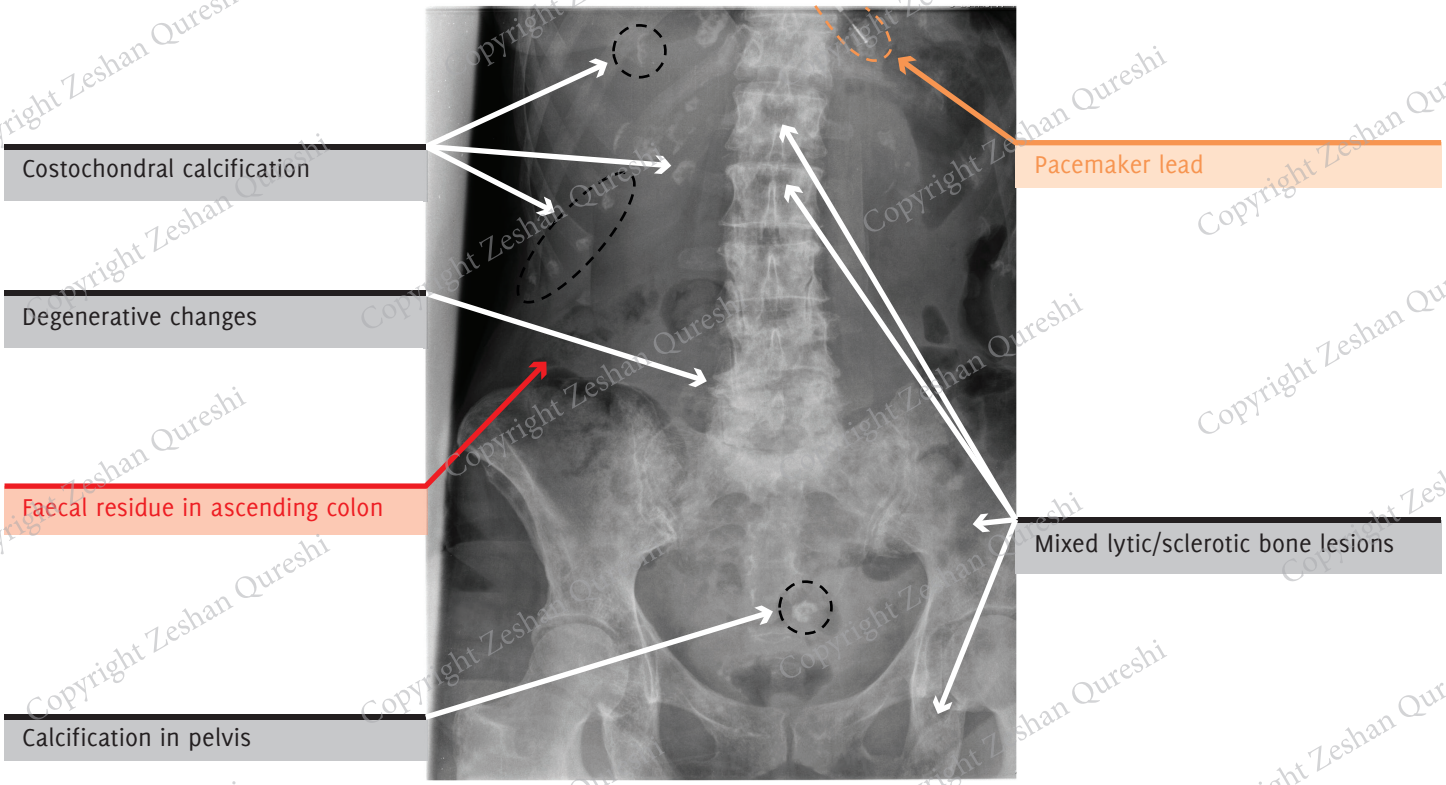

SUMMARY
This X-ray demonstrates multiple mixed lytic/sclerotic bone lesions throughout the degenerative axial skeleton likely to represent metastases secondary to the renal cell carcinoma. There is no evidence of bowel obstruction or pneumoperitoneum. Incidental note is made of the cardiac pacing wire.

INVESTIGATIONS AND MANAGEMENT
The patient should be resuscitated using an ABCDE approach.

Adequate analgesia and hydration should be provided.

Urgent bloods should be taken, including FBC, U&Es, CRP, LFTs, bone profile, blood gas, and tumour markers.

If no recent imaging has been performed, a staging CT scan of the chest, abdomen and pelvis with IV contrast should be considered to assess the known renal cell carcinoma and for disease progression.

The patient should be referred to oncology for further management, which may include biopsy and MDT discussion. Treatment, which may include surgery, radiotherapy, chemotherapy, or palliative treatment, will depend on the outcome of the MDT investigations and the patients' wishes.

ADVANCED

SCENARIO 82

A 52 year old female presents to ED with generalised abdominal pain. She has a complicated past medical history, having had a previous bowel resection with a colostomy in place. She also has a long term congenital bladder defect and she is a non-smoker. On examination, she has saturations of 97% in room air and a temperature of 37.3°C. Her HR is 94 bpm, RR is 20 and blood pressure is 125/72 mmHg. The abdomen is soft and there is generalised tenderness with tinkling bowel sounds. Urine dipstick is unremarkable and a pregnancy test is negative.

An abdominal X-ray is requested to assess for possible bowel obstruction.

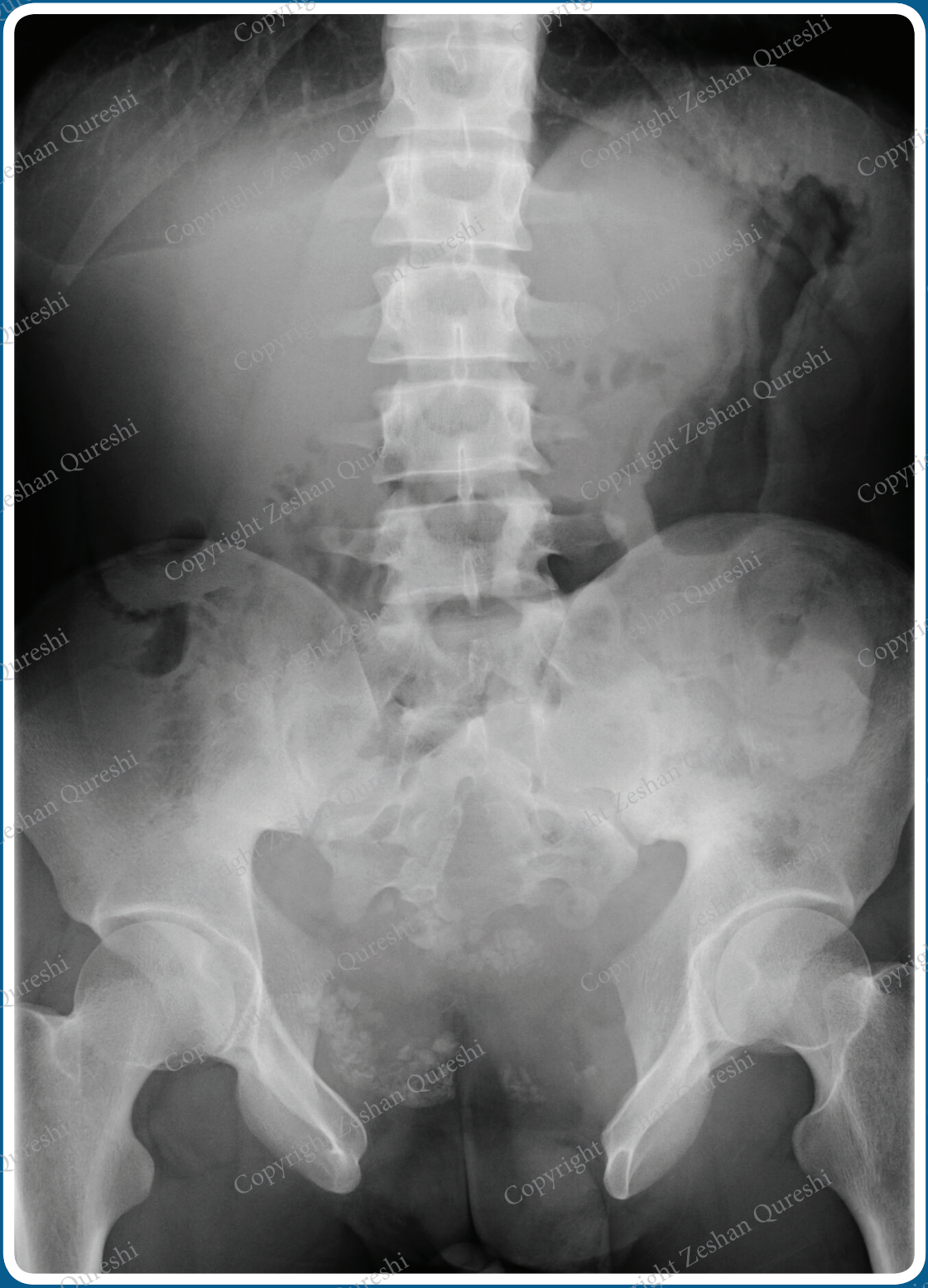

REPORT

Patient ID: Anonymous.
Projection: AP supine.
Rotation: Adequate.
Penetration: Adequate – the spinous processes are visible.
Coverage: Adequate – the anterior ribs are visible superiorly and the inferior pubic rami are visible.

BOWEL GAS PATTERN

The bowel gas pattern is normal.

BOWEL WALL

There is no evidence of mural thickening or intramural gas within the large or small bowel.

PNEUMOPERITONEUM

There is no evidence of free intra-abdominal gas.

SOLID ORGANS

The solid organ contours are within normal limits with no solid organ calcification.

VASCULAR

No abnormal vascular calcification.

BONES

There is a failure of the pubic bones to meet in the midline at the pubic symphysis, termed the 'Manta Ray sign'.

There are no abnormalities of the imaged thoracic and lumbar spine.

SOFT TISSUES

The psoas muscle outline is visible bilaterally.

There appears to be a defect in the extra-abdominal soft tissues in the pelvis, overlying the region of the widened pubic symphysis.

OTHER

There is a rounded radiopaque density projected over the region of the left iliac fossa, in keeping with a colostomy bag external to the patient.

There are several radiopaque calcific densities projected over the region of the abnormally shaped bladder, which represent faceted bladder calculi.

There are no vascular lines, drains or surgical clips.

REVIEW AREAS

Gallstones / Renal calculi: Multiple calculi projecting over the bladder.
Lung bases: Normal.
Spine: Normal.
Femoral heads: Normal.

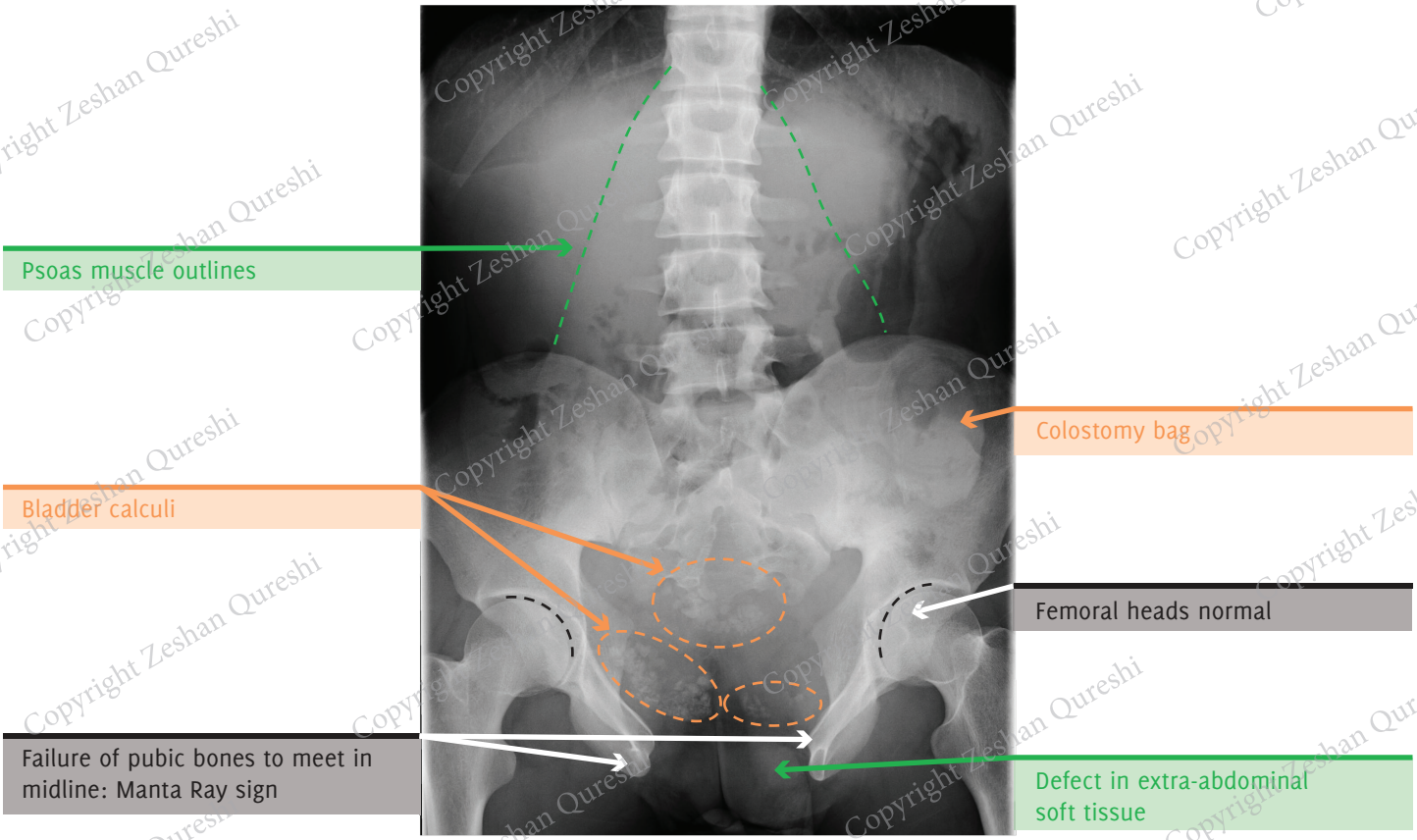

SUMMARY

This X-ray demonstrates a wide separation of the pubic bones termed the 'Manta Ray sign', and a defect in the extra-abdominal soft tissues overlying this region. It also demonstrates several calcific densities projected over the region of an abnormally shaped bladder. Findings are in keeping with bladder exstrophy and vesical calculi formation. Note is also made of the left iliac fossa colostomy.

INVESTIGATIONS AND MANAGEMENT

The patient should be resuscitated using an ABCDE approach.

Adequate analgesia and hydration should be provided.

Urgent bloods should be taken, including FBC, U&Es, LFTs, amylase, bone profile, blood gas, and CRP.

Vesical calculi formation is a known complication following surgery for bladder extrophy. The patient should be referred to the urology team for further management. A CT scan of the kidneys, ureters and bladder might be useful for better visualisation of the anatomy and evaluation of the abdominal pain.

SCENARIO 88

A 27 year old male presents to the gastroenterology outpatient clinic with worsening abdominal pain and a recent history of loss of weight. He has no significant past medical history and is a non-smoker. On examination, he has saturations of 97% in room air and a temperature of 39.2°C. His HR is 112 bpm, RR is 26 and blood pressure is 140/78 mmHg. The abdomen is rigid and there is severe generalised tenderness and guarding with normal bowel sounds. Urine dipstick is unremarkable.

An abdominal X-ray is requested to assess for possible perforation.

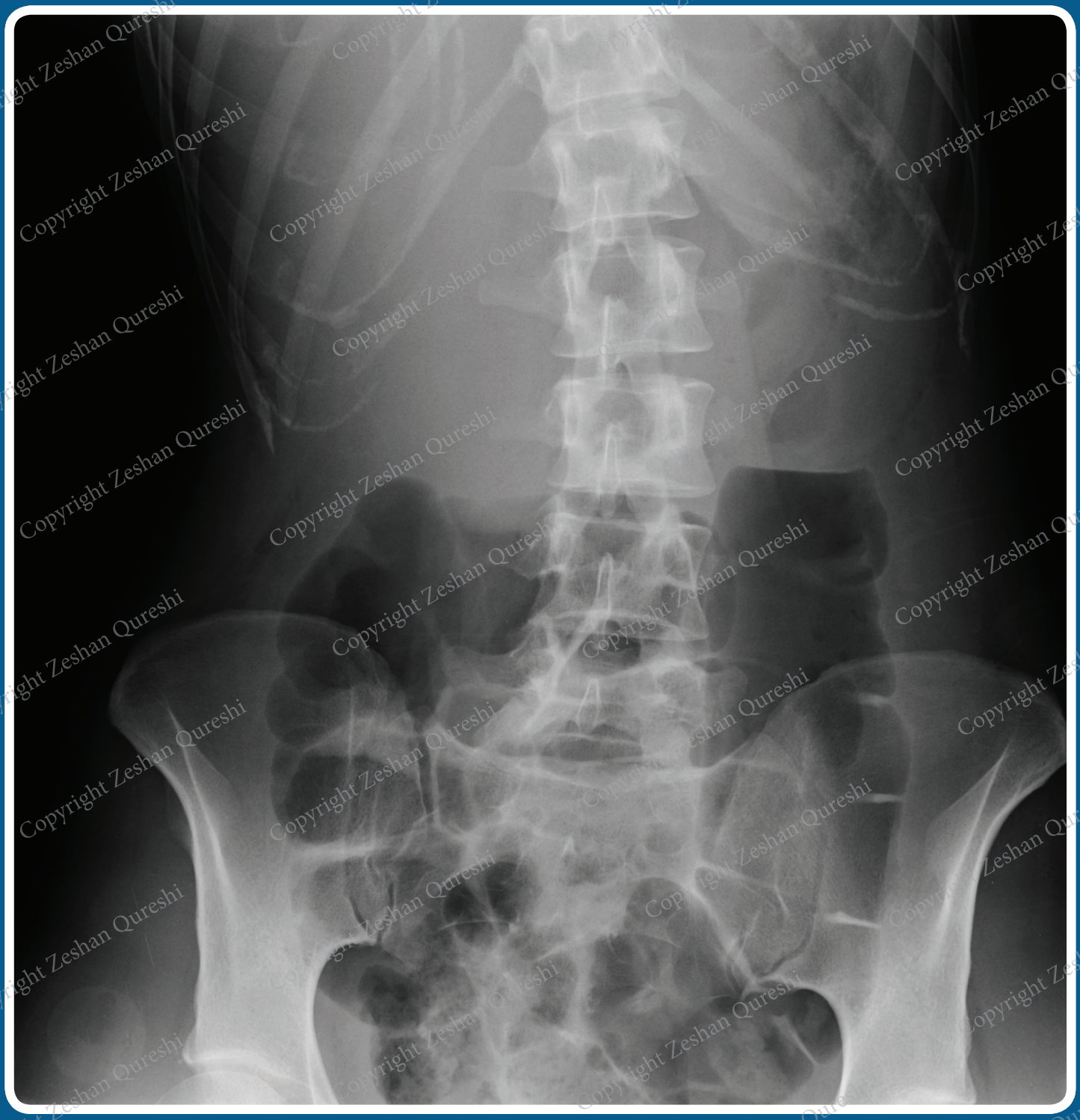

REPORT

Patient ID: Anonymous.
Projection: AP supine.
Rotation: Adequate.
Penetration: Adequate – the spinous processes are visible.
Coverage: Inadequate – the pubic symphysis, inferior pubic rami and hip joints have not been fully included.

BOWEL GAS PATTERN

The large bowel is displaced inferiorly towards the pelvis, implying there is possibly a large soft tissue mass in the upper abdomen.

BOWEL WALL

There is no evidence of mural thickening or intramural gas within the large or small bowel.

PNEUMOPERITONEUM

There is no evidence of free intra-abdominal gas.

SOLID ORGANS

The solid organ contours are within normal limits with no solid organ calcification.

VASCULAR

No abnormal vascular calcification.

BONES

There is mild lumbar scoliosis convex to the left, centred at the L2/L3 level.

There are no other abnormalities of the imaged thoracic and lumbar spine, or within the pelvis.

SOFT TISSUES

The psoas muscle outline is not preserved on the right side which may relate to the presence of an abdominal mass.

The extra-abdominal soft tissues are unremarkable.

OTHER

There is a large homogeneous opacification seen in the upper abdomen, which is displacing the large bowel down into the pelvis.

There are no vascular lines, drains or surgical clips.

REVIEW AREAS

Gallstones / Renal calculi: No radiopaque calculi.
Lung bases: Normal.
Spine: Lumbar scoliosis seen convex to the left, centred on the L2/L3 vertebral bodies.
Femoral heads: Not visible.

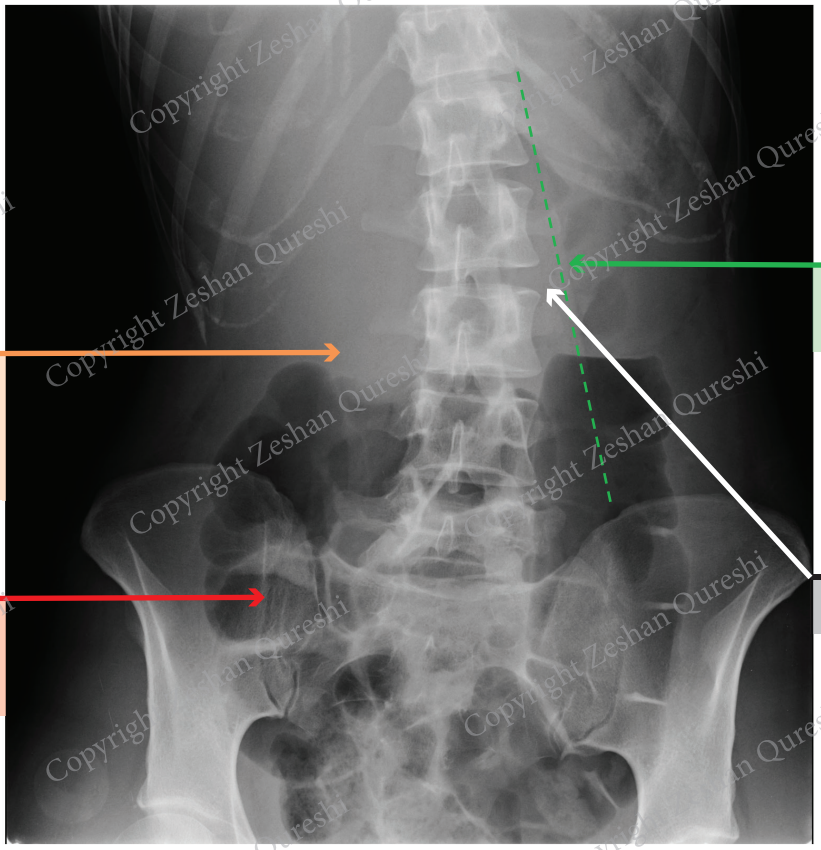

SUMMARY

This X-ray demonstrates a large homogeneous opacification in the upper abdomen, which is displacing the large bowel inferiorly into the pelvis and obscuring the right psoas muscle outline. Given the clinical history, findings are suggestive of a large abdominal mass, which is probably retroperitoneal due to the loss of the right psoas muscle outline. The mild lumbar scoliosis is likely relative to this.

INVESTIGATIONS AND MANAGEMENT

The patient is clinically unwell and should be resuscitated using an ABCDE approach.

Adequate analgesia and hydration should be provided.

Urgent bloods should be taken including FBC, U&Es, LFTs, amylase, bone profile, CRP, blood gas, and blood cultures.

The sepsis 6 pathway should be started immediately, including administration of oxygen, IV broad spectrum antibiotics and consideration of a fluid bolus as well as measurement of lactate and urinary output and blood cultures.

A CT scan of the abdomen/pelvis with IV contrast would be useful for better visualisation of the anatomy and the general surgical team should be involved.

CASE INDEX

INDEX

*Page numbers followed by *f* indicate figures.